

# ANTHROPOGENIC THREATS TO THE SEA TURTLE POPULATIONS ALONG THE BRAZILIAN COAST

Cecília Baptistotte<sup>1</sup>, Gustave Lopez<sup>2</sup>, Denise Reith<sup>1</sup>, Marcelo Renan de Deus Santos<sup>3</sup>, Marçillo Altoé Boldrin<sup>3</sup>, Max Rondon Werneck<sup>4</sup>, Henrique Becker<sup>5</sup>, Daphne Wrobel Goldberg<sup>6</sup>, Gustavo David Stahelin<sup>6</sup>, Maria Ângela Marcovaldi<sup>2</sup>, Thaís Pires<sup>2</sup>

<sup>1</sup>Projeto TAMAR/ICMBio - Av. Paulino Muller, nº 1.111, CEP 29.040-715. Vitória-ES, Brazil. <sup>2</sup>Fundação Pro-Tamar - Rua Rubens Guelli 134, sala 307, Ed. Empresarial Itaigara, CEP:41815-135, Salvador, Bahia, Brazil. <sup>3</sup>Centro Universitário Vila Velha - UVV-ES - R. Comissário José Dantas de Melo, nº 21. CEP 29.102-770, Vila Velha- ES, Brazil. <sup>4</sup>Bw Consultoria Veterinária - R. Ponciano Eugênio Duarte, nº 203. CEP 11680-000, Ubatuba- SP, Brazil. <sup>5</sup>Fundação Pro-Tamar - Rua Antonio Athanasio da Silva, 273 Itaguá - Ubatuba - SP, CEP 11680-000, Brazil. <sup>6</sup>Fundação Pro-Tamar - Rua Professor Ademir Francisco, 140 - Barra da Lagoa SC, CEP: 88061-160, Brazil.

Post mortem examination is an important tool in sea turtle diseases investigation and its relation to anthropogenic stressors. In order to identify the possible causes of sea turtles strandings, Projeto TAMAR-ICMBio conducts necropsies at its research stations along the Brazilian coast. Moreover, TAMAR has developed research agreements through veterinary universities research programs to allow more accurate diagnostics. In this study, we analyze results from 989 necropsies performed at TAMAR Stations in Bahia, Espírito Santo, São Paulo and Santa Catarina States (Figure 1), from January 2009 to May 2011.

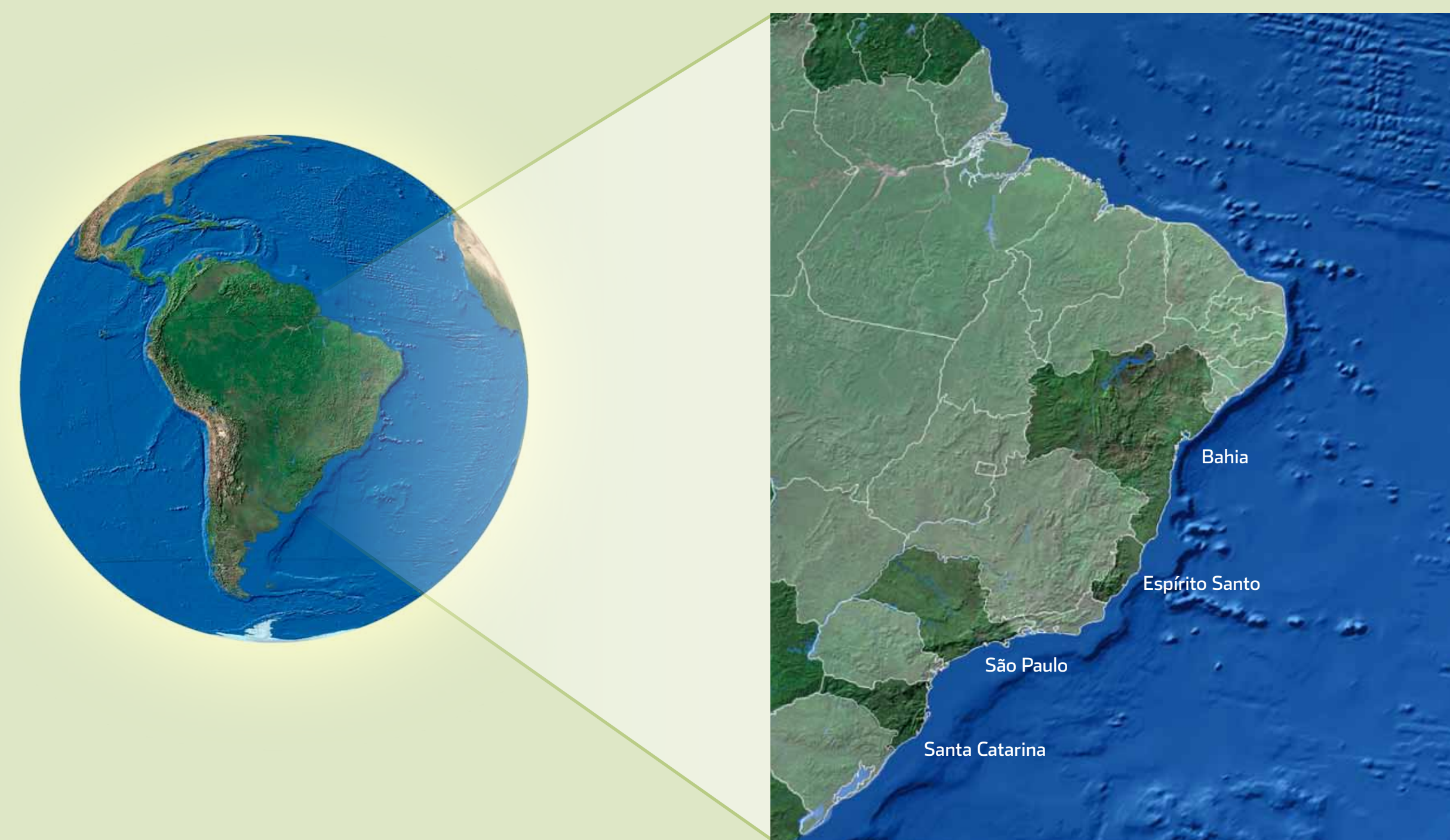


Figure 1. States where the Tamar stations named above are located.

During this period, we examined necropsy findings from 920 *Chelonia mydas* and 69 *Eretmochelys imbricata*. The samples from Bahia and Espírito Santo included respectively 191 and 372 *C. mydas* and 49 and 20 *E. imbricata*. Two hundred and seventy two *C. mydas* were necropsied at the Ubatuba Station, in São Paulo, and 85 at the Florianópolis Station, in Santa Catarina. Among these animals, 93% were juveniles, with the curved carapace length (CCC) varying between 0.25 and 0.48 cm.

In 33% of the necropsied *C. mydas*, drowning was characterized as the main cause of death, which may provide a strong indication of fishing interaction. Thirteen percent of the animals, had gastrointestinal lesions (not related to debris ingestion) and 10% had their death related to marine debris ingestion. Sixteen percent of the individuals died as a result of other health disorders, and in 28% of the turtles, it was not possible to determine the cause of death. In hawksbill turtles, a 33% incidence of gastrointestinal complications was observed, as well as 30% of marine debris ingestion and 7% of drowning signs. 17% had other types of health disorders and in 13% it was not possible to determine the cause of death.



Figure 4. Juvenile *C. mydas* with a fracture on the right side of the carapace.


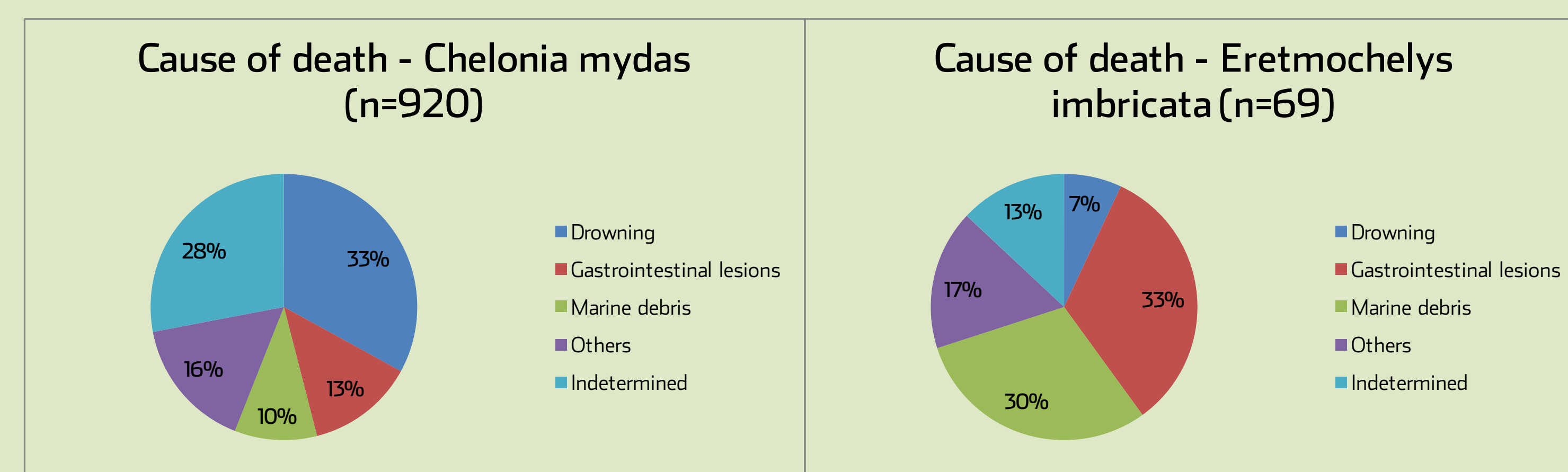


Figure 5. Juvenile *C. mydas* drowned following entanglement in a fishing net.

Although information concerning sea turtles health conditions is scarce, it is possible that data on specific cases, may improve post mortem diagnosis. The results show that drowning is the first leading cause of death, which suggest possible fishery interaction. Secondly, lesions along the gastrointestinal tract indicate marine pollution, specially marine debris ingestion as a relevant threat. These information can be useful to improve the knowledge on sea turtles threats and consequently indicate some conservation actions.



Graphic 1. Causes of mortality among *Chelonia mydas* specimens examined by necropsy in Brazil.

Graphic 2. Causes of mortality among *Eretmochelys imbricata* specimens examined by necropsy in Brazil.



Figure 2. Large bowel obstruction caused by the presence of fecaloma in a juvenile *Chelonia mydas*.

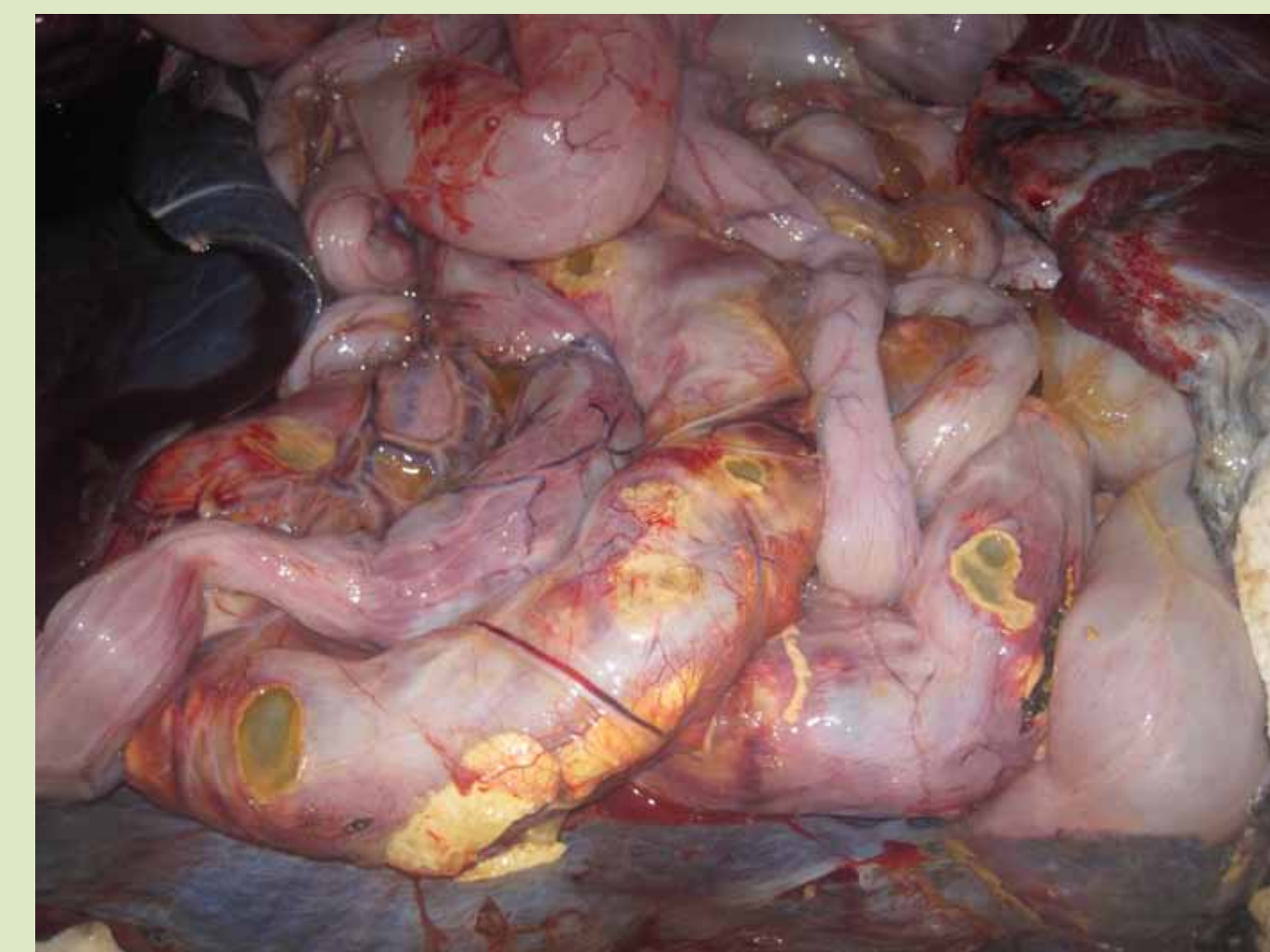

Figure 3. Presence of ulcers on the serosal surface of the large intestine.



## Acknowledgements

We would like to thank the Tamar personnel who carried out the fieldwork and also the local communities. Projeto TAMAR, a conservation program of the Brazilian Ministry of the Environment, is affiliated with ICMBio (the Brazilian Institute for Biodiversity Conservation - Instituto Chico Mendes) and co-managed by Fundação Pró-TAMAR.